

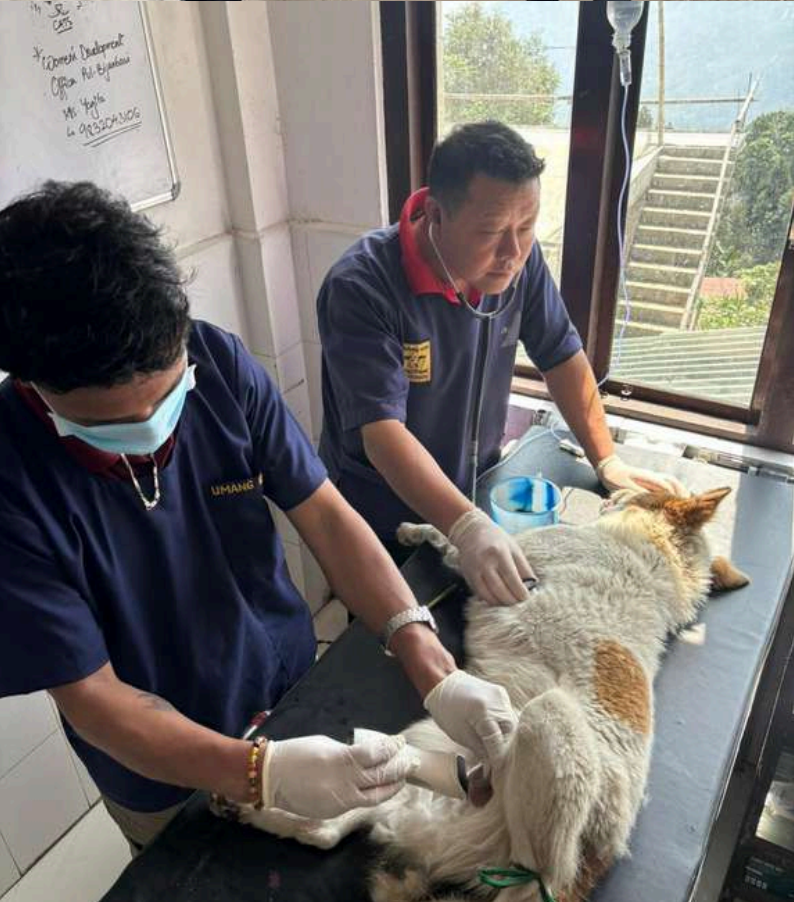
# DARJEELING ANIMAL SHELTER



**May: A Month of Extraordinary Resilience and Lifesaving Rescue**  
May has been an absolute whirlwind at the Darjeeling Animal Shelter. If we had to describe the past few weeks in a single word, it would be eventful. From the bustling streets of town to the highest peaks of the district, our team has been stretched to its limits—and time and again, they have proven their unwavering dedication to the animals of Darjeeling.



# May in Focus: A Glimpse into Our Month of Miracles 📷 ✨



Credits to the shelter backbone:


Naren Pradhan, Wangal Tamang , Rudra Thapa , Sisir Rai , Umang Gurung, Sajjan Rai , Anurag Chettri , Gaurav Tamang , Furmit Lepcha , Kanchan Tamang.

# MAY HIGHLIGHTS

STERILISATION	DOG	CAT
SPAYING	73	2
CASTRATION	31	3

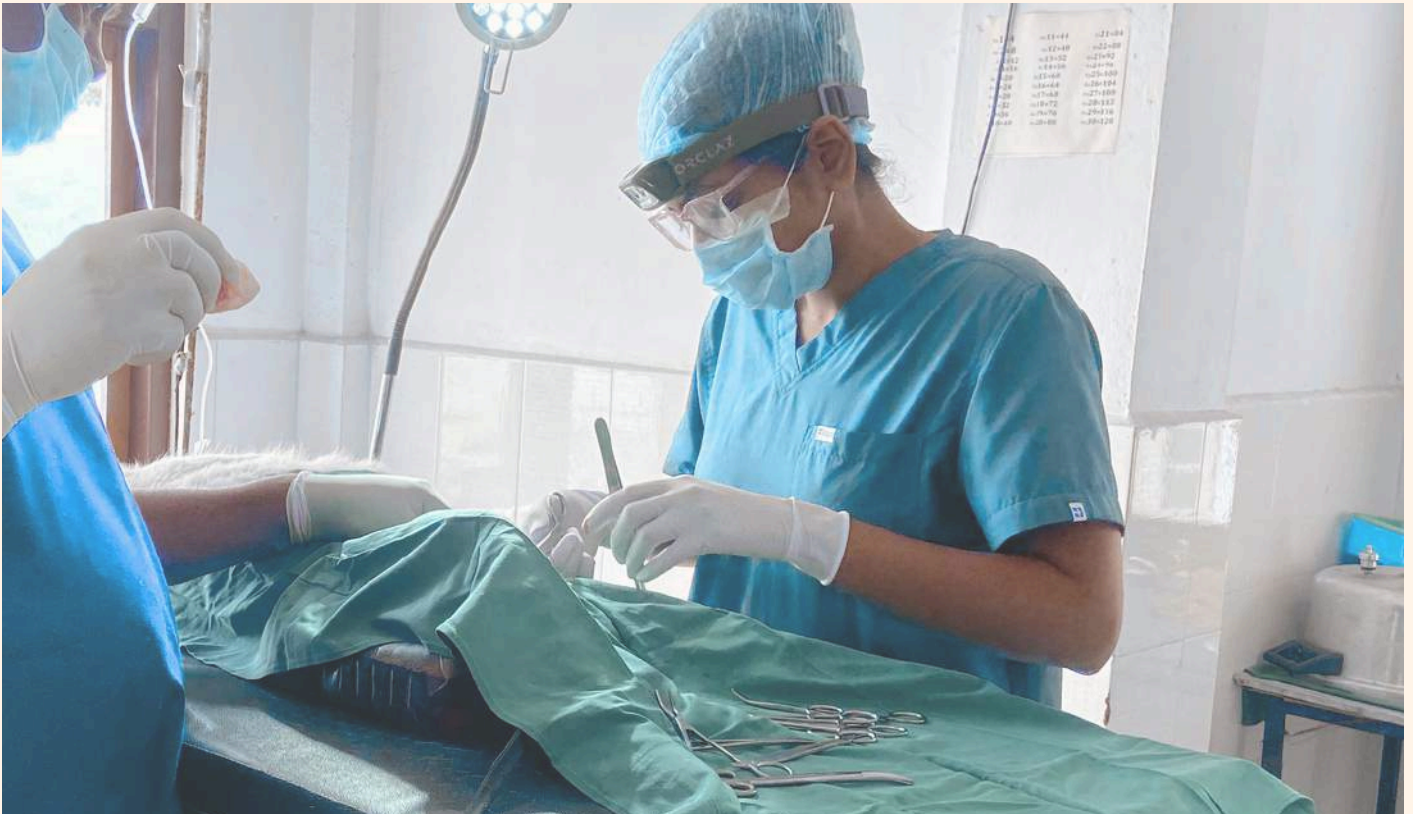**total ABC-109**

CLINICAL ACTIVITIES	DOG	CAT
CASES TREATED	497	38
RESCUE	26	0
ADOPTION	3	5
X-RAY	10	0
SPECIAL SURGERIES	10	0
ARV	91	3



## ABC ACTIVITIES ON THE MONTH OF MAY

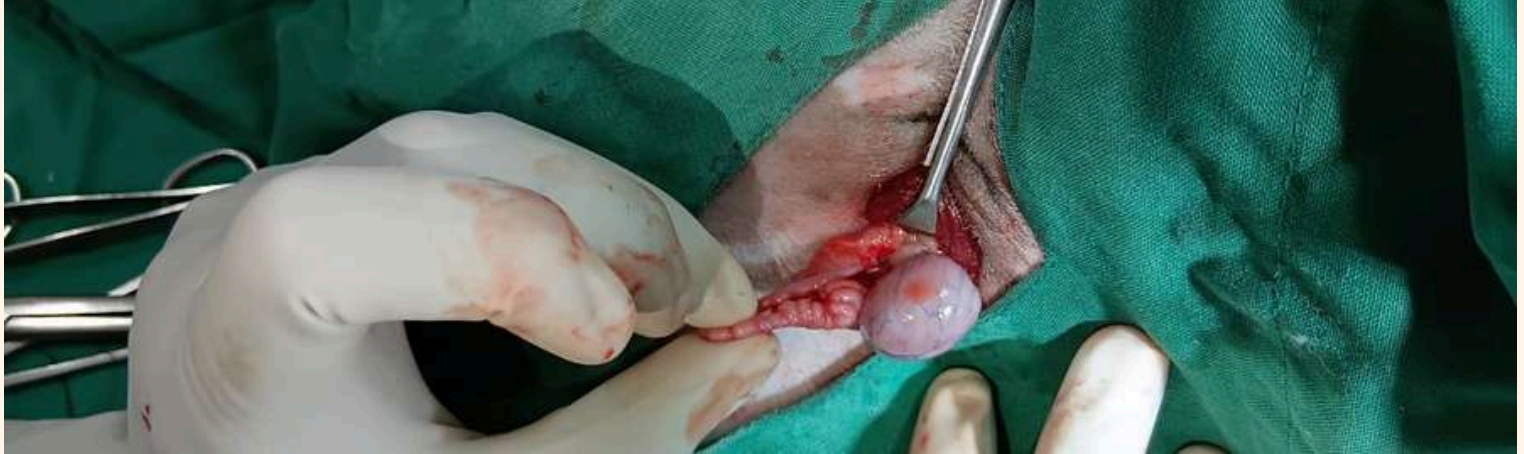This month, our Darjeeling shelter actively carried out Animal Birth Control (ABC) Program surgeries in double the number compared to last numbers along with rescue operations, mobile treatments, and various surgical procedures for needy animals.



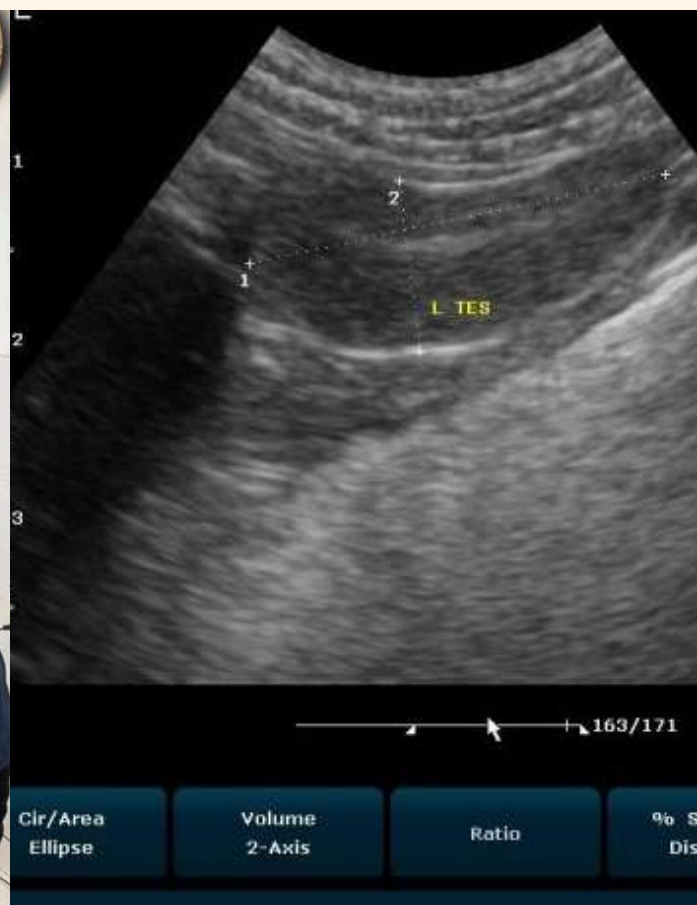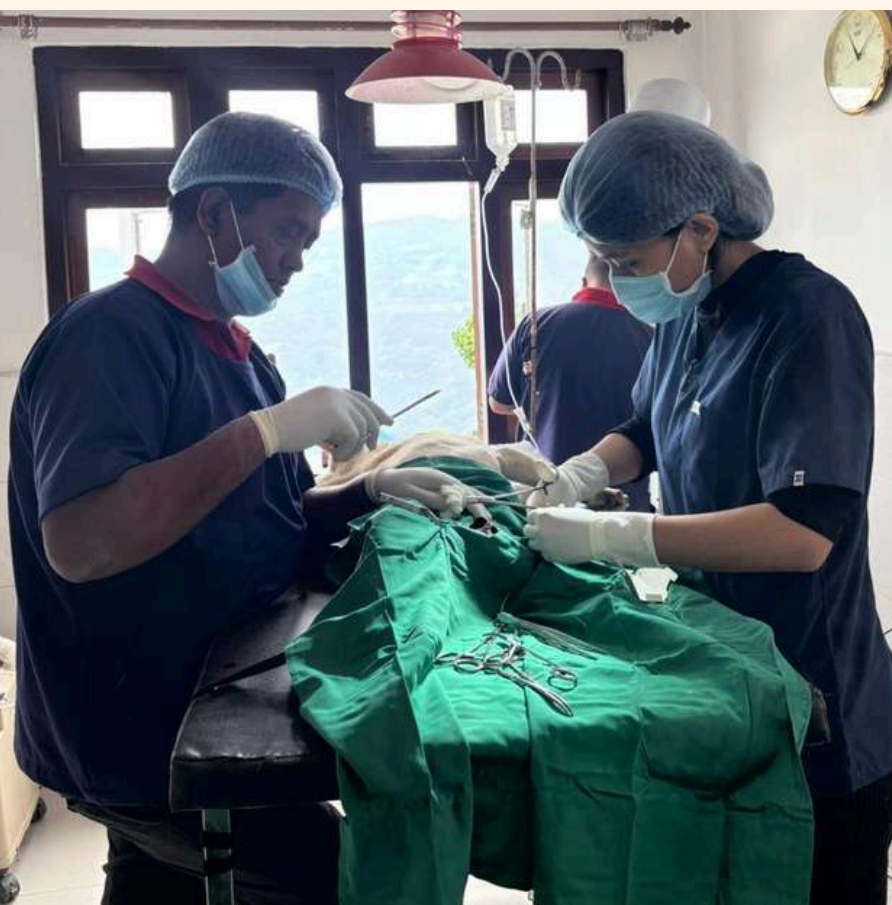Through these efforts, we continued our commitment towards animal welfare and community service.

## ***Cryptorchid Dog Castration Surgery***

A cryptorchid dog was successfully treated through surgical castration. The retained testicle was located and carefully removed under sterile surgical conditions to prevent future complications such as testicular tumours and hormonal disorders.

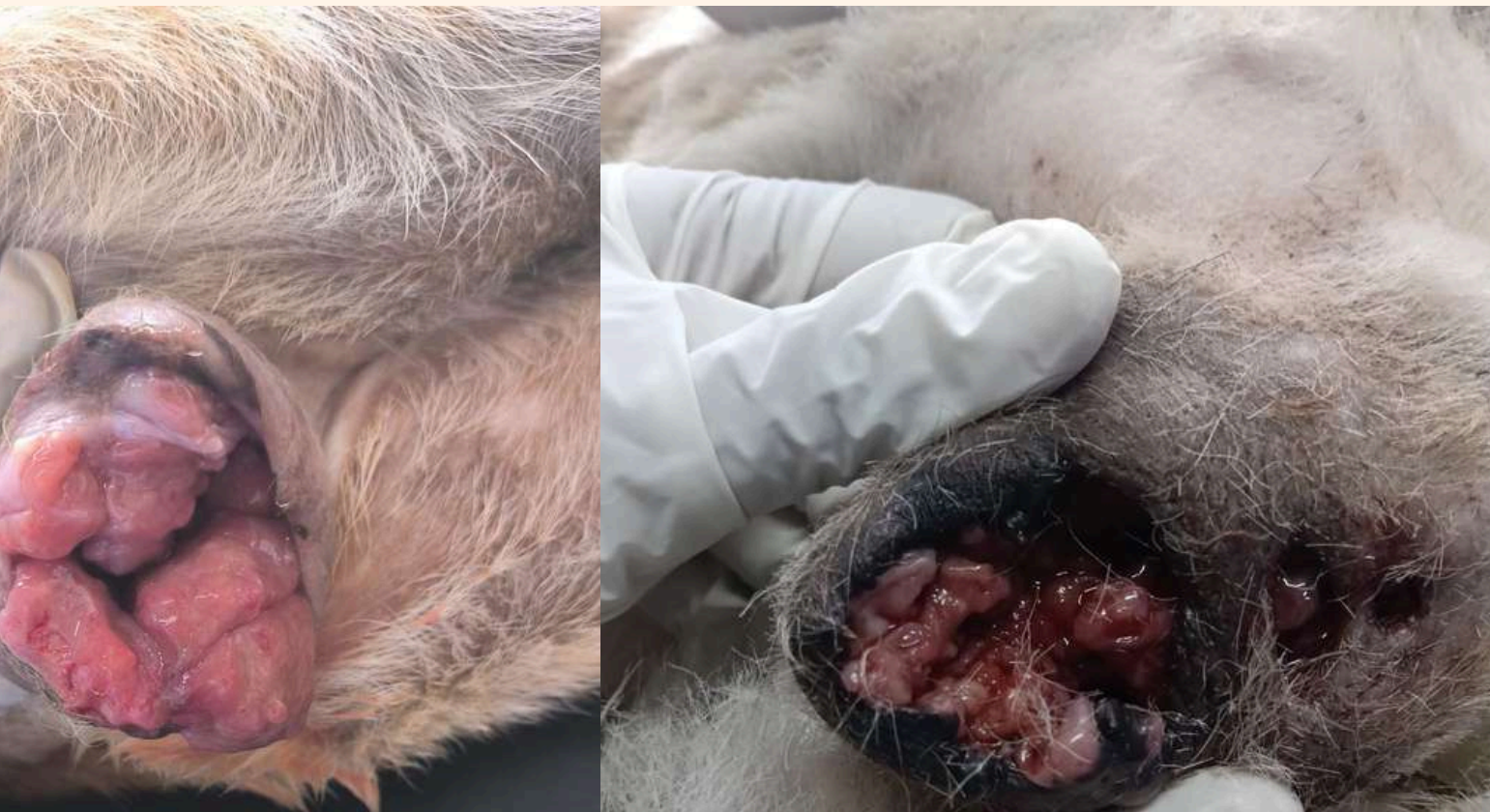

The dog recovered well after surgery and is currently under post-operative care and observation. This case highlights the importance of early diagnosis and timely ABC intervention in cryptorchid dogs for better animal health and population control

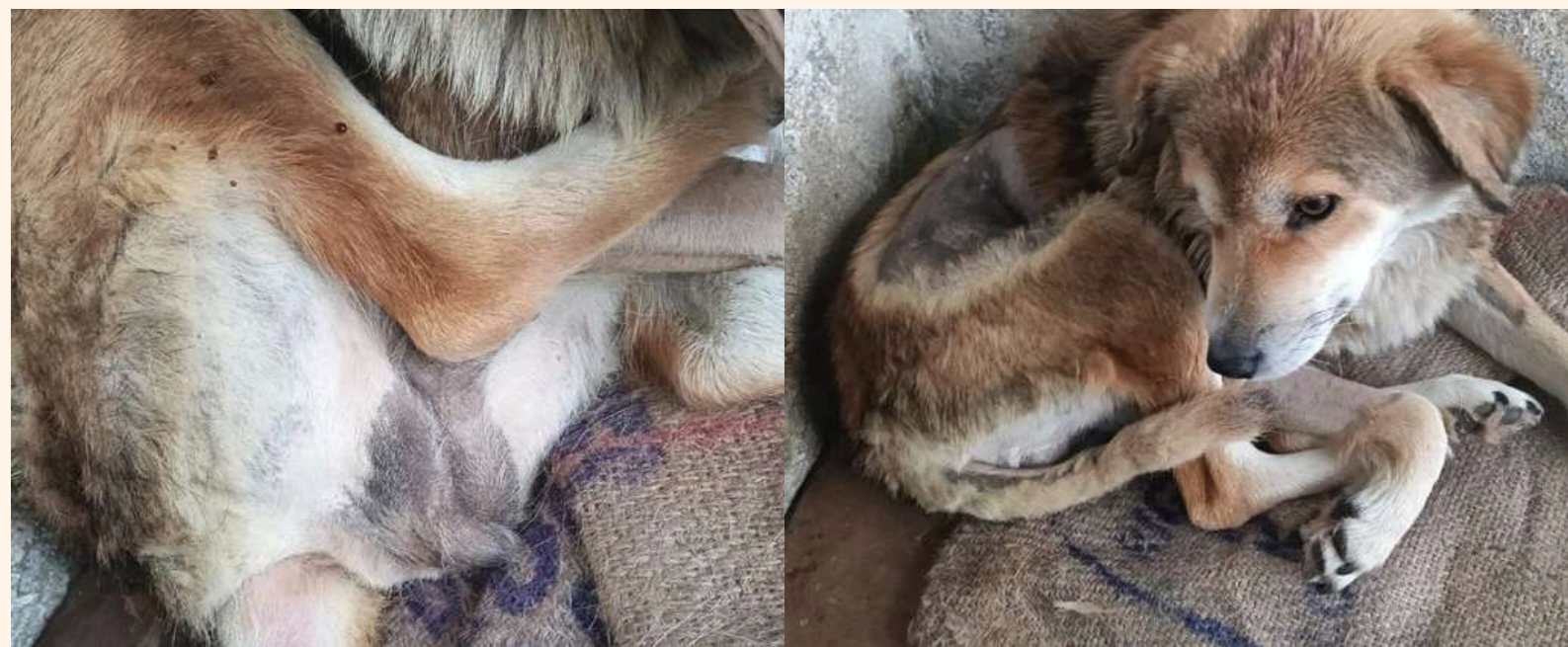

## ***Transmissible Venereal Tumour in Dogs.***

During this month, multiple cases of Transmissible Venereal Tumor (TVT) were treated in both male and female dogs at DAS. The affected animals were clinically examined and managed with appropriate treatment protocols and supportive care. Regular monitoring and follow-up sessions were conducted to assess recovery and improve overall health conditions.



Along with TVT treatment , ABC surgeries were also successfully performed on the dogs. The cases responded positively to treatment, and continuous care was provided to ensure better welfare and rehabilitation of the shelter dogs



## ***From Trauma to Recovery: RTA Case Updates***

Unfortunately, this peak tourist season has had a heavy impact on our street animals, leading to a heartbreaking spike in road traffic accidents (RTAs) across Darjeeling.

Our rescue team and clinic have been pushed to the limit responding to these high-stakes emergencies.



Yet, out of the heartbreak came incredible triumph—thanks to the swift action of our rescuers and the dedication of our medical team, this month has also been defined by huge, miraculous recoveries

### **Credits to informer's of Road Traffic Accident:**

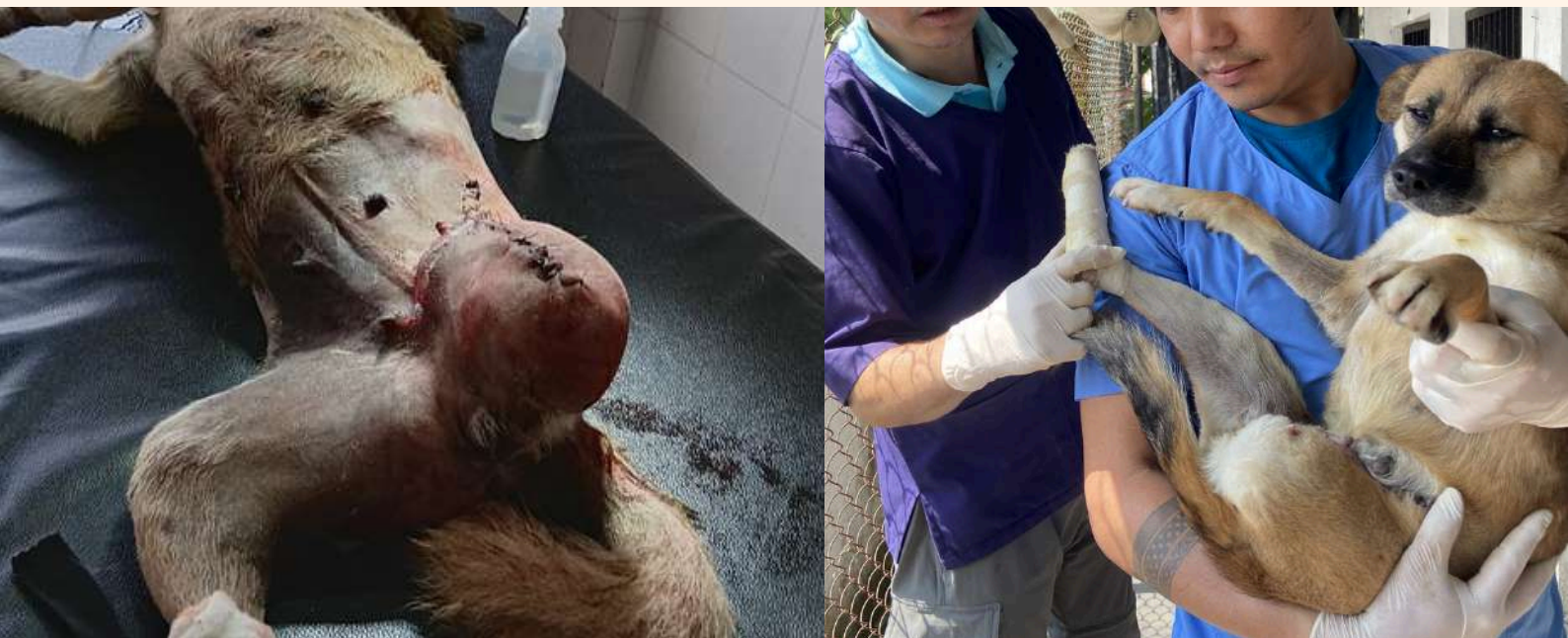**Dr. Seuden , Christiane , Nita Tamang ,  
Temba Bhutia.**

## From Tragedy to Triumph: A Miraculous Recovery for a Brave Survivor 🐾

During the month, a heartbreaking emergency brought a severely debilitated, 13kg dog to our care after a devastating road traffic accident in Jorbungalow. He was rushed to the shelter in the morning hours after a hit-and-run left him in critical condition



Upon his arrival, our rescue team immediately sprang into action to assist her. The veterinary team provided urgent medical care, aggressive pain management, and emergency amputation was performed which hindered our ABC schedules but prioritising emergency case over everything a successful operation was carried out.

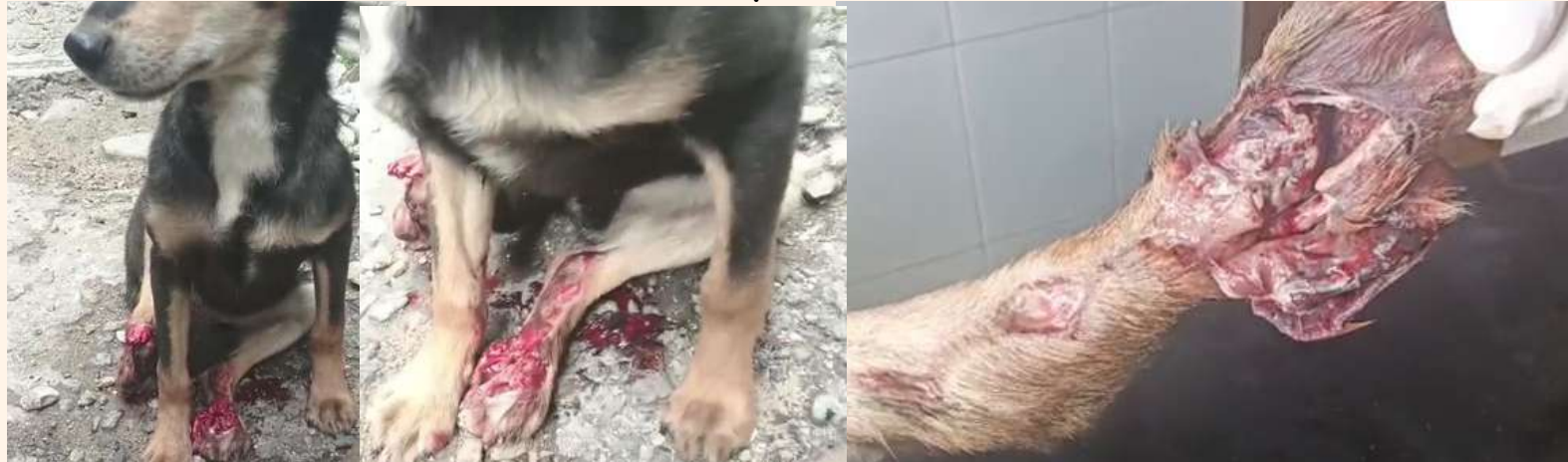

**The high-stakes amputation was completely successful, and despite his initial weakness, this brave girl is fighting hard and gradually recovering.**

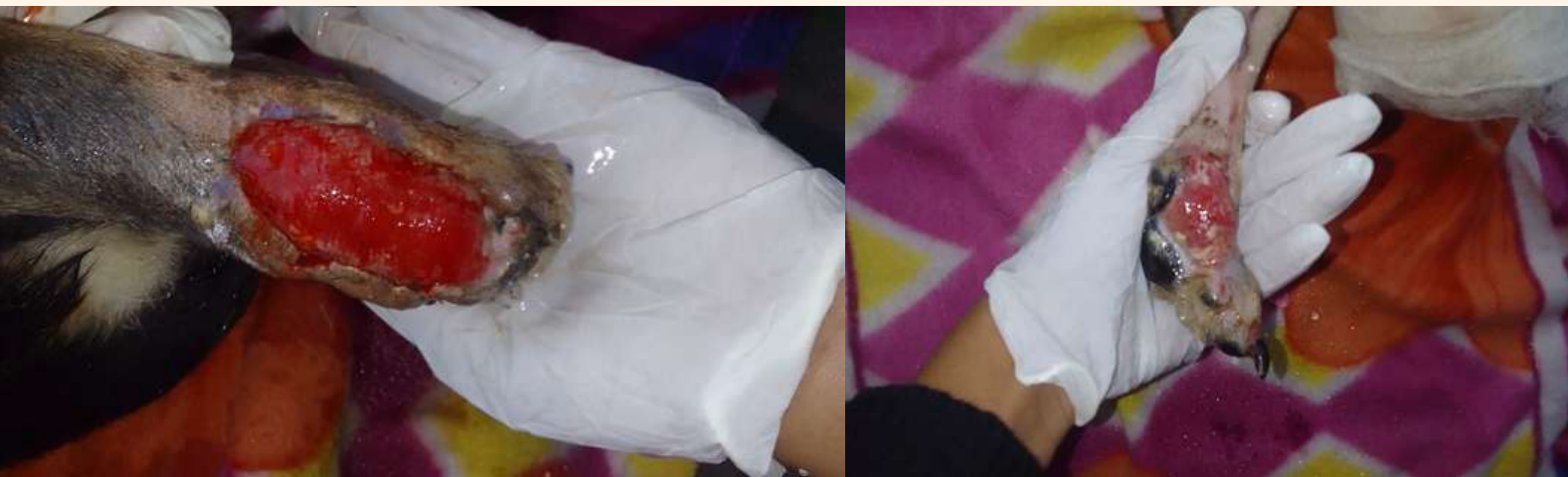## ***A Second Chance for a Little Survivor***

**🐾 The Arrival: Facing a Catastrophic Emergency.**

Our shelter faced one of its most heart-wrenching road traffic accidents when a tiny, vulnerable puppy was rushed to us in critical condition. The high-impact collision had been devastating.



However, defying all expectations, this little pup made a spectacular, full recovery in just four weeks. After a month of intensive care and Rehabilitation.

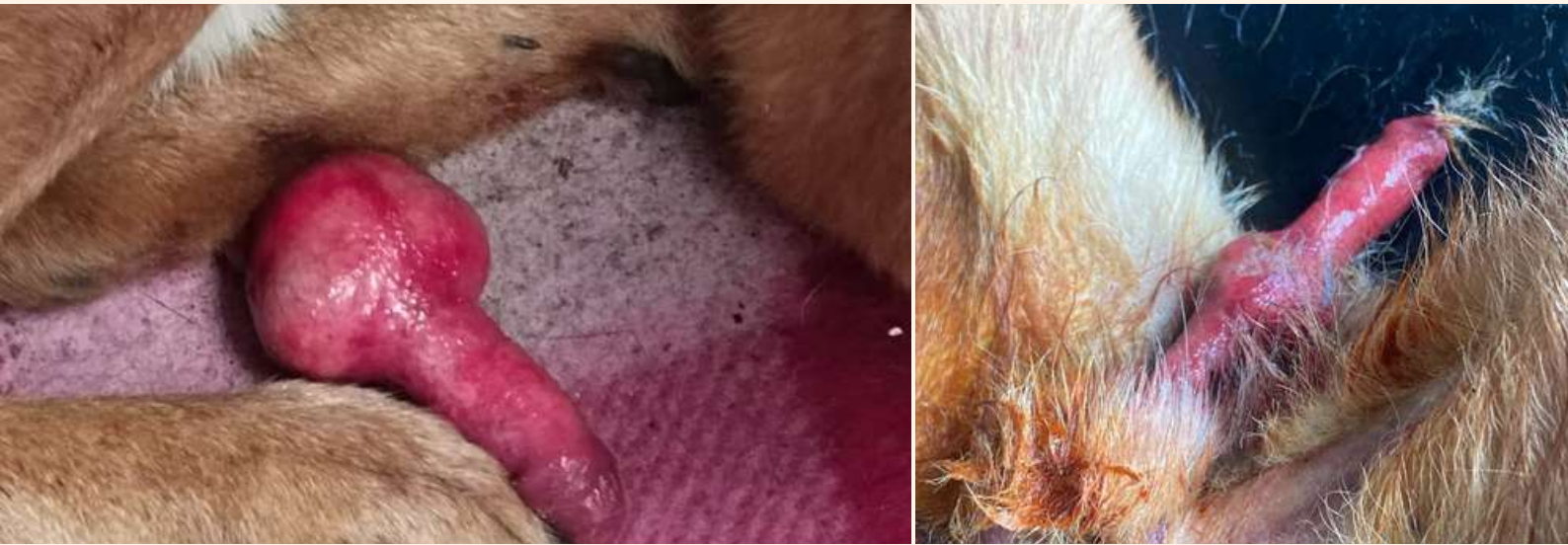

**🐾 Seeing her return to her familiar territory, fully mobile and happy, was the perfect reward for our tireless veterinary and rescue team, and a powerful testament to her unbeatable fighting spirit and the immense value of timely, expert emergency care. Her story is a beautiful reminder of why we do this work.**



## ***Overcoming a Devastating Case of Cruelty and Injury Surgical Triumph: Successful Management of Traumatic Penile Detachment***

Our shelter team was presented with a highly critical emergency involving an animal suffering from severe trauma and complete penile detachment, as documented during the initial assessment.



The image shows the severed Penis and severely compromised tissue, presenting a tense and complex surgical challenge.



Despite the high-stakes nature of the injury, the clinical team maintained absolute calm and precision. Immediate emergency reconstructive surgery was performed to debride the damaged areas, realign the anatomy, and restore urethral patency. We are incredibly pleased to report that the patient has made an excellent recovery; he is now urinating normally without discomfort and has completely regained his appetite.

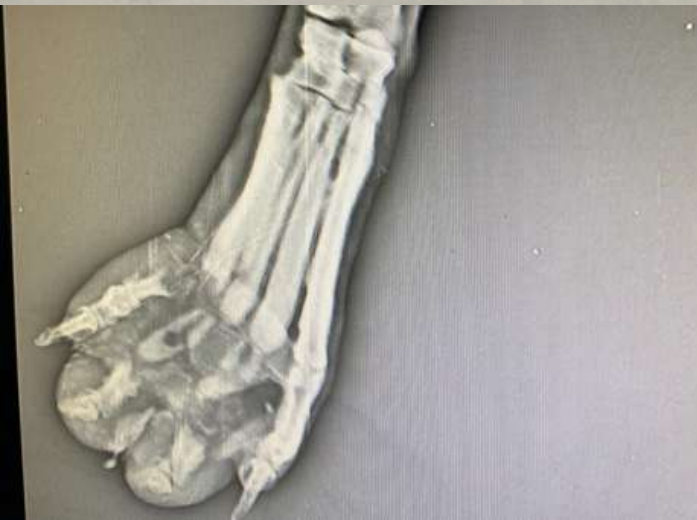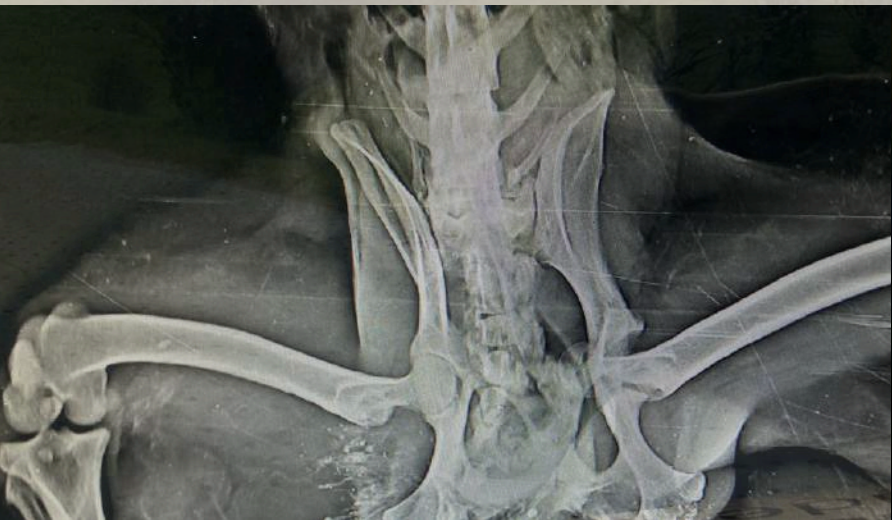## Sandakphu Heights: A High-Altitude Rescue 🏔️🐾

The Rescue: We pulled off a grueling, high-altitude rescue from Gairibas in Sandakphu after receiving a critical tip-off from a friend of one of our trustees.



The Case: This was a heartbreaking, chronic situation. The poor animal was a victim of a two-month-old road traffic accident and was entirely non-weight-bearing on both hind limbs. The medical exam revealed a severe hip dislocation alongside complete phalanges (toe bone) fractures.

The Outcome: Because the trauma was so old and severe, our veterinary team performed a successful amputation to finally eliminate the chronic pain. The patient is now resting comfortably in our clinic, and we are closely monitoring their progress day by day.



Location: Gairibas, Sandakphu 📍

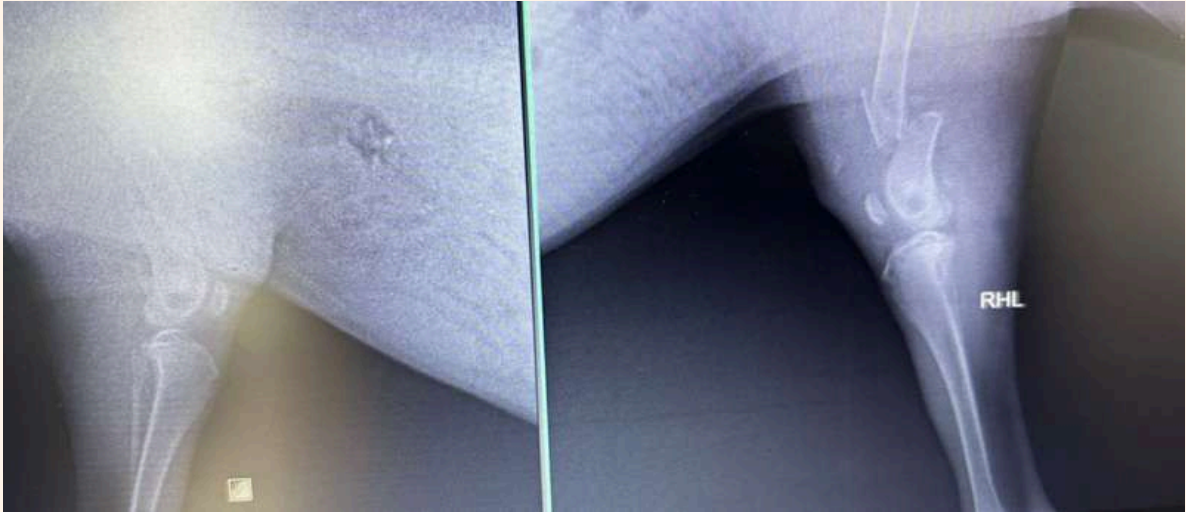
- Condition: 2-month-old RTA, hip dislocation, and shattered phalanges. 🩹
- Status: Amputation successful; stable and under close watch. 🩺❤️

Credits to informers: Fiorenza Bortolotti and Christiane

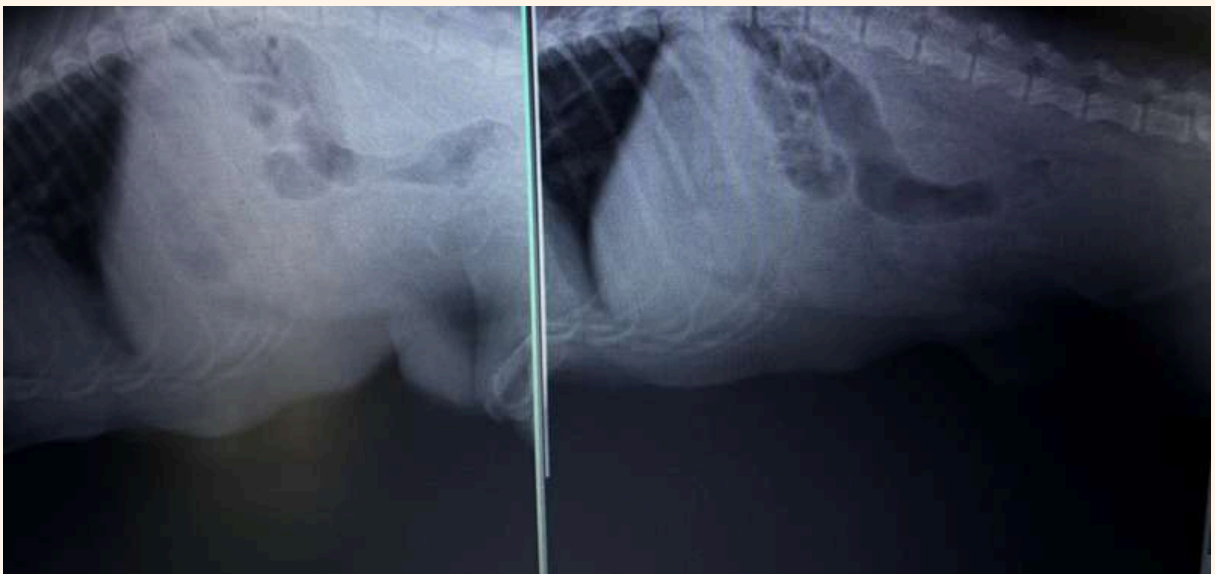
## Bridging the Gap: Taking Giant Leaps in Diagnostics 🩺

This month marked the beginning of a major shift in our approach to medicine, focusing heavily on advanced diagnostic screening. Even though we are still frequently struggling to meet the basic needs of running an X-ray department—we have tried our best to bridge the gap.

Through sharp clinical observation, careful physical exams, and sheer determination, we successfully established a definitive diagnosis for nearly every single one of our rescued dogs this month.



Pinpointing the exact nature of these complex fractures, internal traumas, and chronic conditions has completely transformed our treatment plans, ensuring that every patient receives the highly specific, targeted care they need to heal properly



The Challenge: Persistent logistical struggles with basic X-ray needs. 🏠

The Victory: Definitive diagnoses achieved for the vast majority of our rescued dogs, ensuring precise and effective treatment! 🎯🐕

## Finding Forever: A Month of Happy Adoptions 🏠❤️



It has been an incredibly rewarding month for our rehoming program, with multiple rescued dogs and cats officially stepping out of the shelter and into the arms of loving forever families!



Along the many heartwarming success stories was a special dog suffering from rickets. Because of his bent legs and nutritional bone disease, finding a home for a pup with special needs can be a long and difficult journey. However, a compassionate adopter looked past his condition and fell completely in love. Today, he and our other rescued pets are finally sleeping soundly in warm, safe homes of their own.



The Milestone: Multiple dogs and cats successfully adopted this month! 🐶🐱  
Special Highlight: Our brave pup with rickets found his perfect forever family. 🍖

# Every Little Amount, A Giant Leap for the Voiceless 🐾🐾

Every single donation, no matter how small, has been of monumental help to our clinic and rescue operations this month.

It is entirely through the trust of each and every person in our supporters' network that we are able to build a safe, strong community for the voiceless.

Your shared belief in our mission is the foundation that allows our veterinary team to step into the clinic every single morning, ready to turn heartbreaking accidents into miraculous recoveries.

The Power of Small Gestures: Every micro-donation directly funded life-saving surgeries and critical post-op care. 🩺

A Heartfelt Thank You: From the tiny pup walking on four legs again to our resilient amputees, we thank you for being their voice.



—Dr. Anna Pradhan

—Dr. Monica Prajapat